

# Reopen the pipeline

**Learn why a vein or catheter may become occluded, how to head off trouble, and what to do if your patient has problems.**

BY LYNN C. HADAWAY, RN,C, CRNI, MEd

WALTER ZINKOFF, 77, has bacterial endocarditis and receives vancomycin through a peripherally inserted central catheter (PICC). Attempting to flush the catheter before infusing his next dose, you encounter a lot of resistance and can't aspirate blood. Mr. Zinkoff tells you that his last dose took 2 hours to infuse—twice as long as normal.

You should get a free-flowing blood return whenever you use a syringe to gently aspirate from any intravenous (I.V.) catheter, so you're facing a problem. To protect Mr. Zinkoff from serious complications, investigate whether a thrombus or something else is occluding his PICC or the vein where it resides before you try to inject or infuse anything through it.

The vein and the catheter are two distinct flow systems, each vulnerable to occlusion during I.V. therapy. The causes of vein and catheter problems vary, as do prevention and management techniques. In this article, I'll discuss problems that can affect catheters in both peripheral and central veins, explain what you can do to protect your patient from injury, and offer suggestions that may help you save a line.

## Problems with peripheral catheters

Because their tips remain in peripheral veins, both short peripheral and longer midline catheters are considered peripheral catheters.

A **short peripheral catheter**, less than 3 inches (7.5 cm) long, is typically placed in a small, superficial vein of the hand or arm. If the I.V. bag runs dry and blood backs up, a thrombus can occlude the catheter. If the dressing doesn't adequately stabilize the catheter, movement can cause the external portion to kink or the internal portion to damage the vein wall and trigger thrombosis. (You'll learn more about how

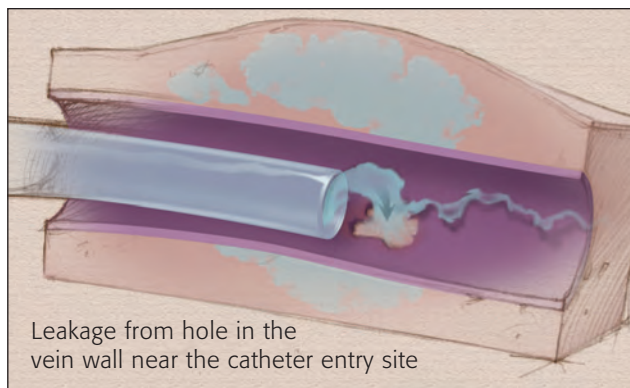
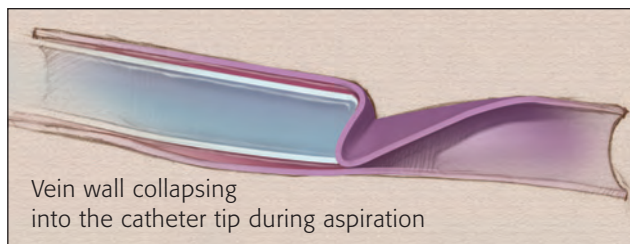
thrombosis develops later.) Phlebitis or infiltration also can slow or stop the flow of fluid.

Routinely assess your patient's hand and arm where the I.V. device was placed. Look for reddened, blanched, tight, translucent, or cool skin; swelling; pain; numbness; streak formation; a palpable venous cord; purulent drainage; and circulatory impairment. If you detect any of these problems, immediately remove the peripheral catheter.

Although blood return is a key assessment finding in I.V. therapy, inability to get a blood return isn't a sure sign of occlusion in a peripheral catheter. Aspirating from a catheter resting in a small-diameter vein could collapse the vein wall into the catheter tip to block the backflow of blood. Assess your patient for other signs and symptoms of complications and try other ways to get a blood return. For example, hold the I.V. bag lower

than the catheter or gently pinch the administration set near the catheter. If you still don't get blood return, replace the catheter.

Even when you get a brisk blood return from a peripheral catheter, you can't rule out complications if other problem signs are present. For example, swelling around the insertion



site may indicate a hole in the vein wall near the catheter tip in addition to the one where the catheter entered the vein. (See *Assessing for problems and responding* for details.)

MICHAEL KREISS-RUSSECK

# for I.V. therapy

## ASSESSING FOR PROBLEMS AND RESPONDING

If the infusion rate of any I.V. catheter is sluggish or you can't withdraw blood, look for obvious problems such as the external part of the catheter kinked or tubing trapped under the patient. If you don't detect a problem, follow these guidelines, depending on the catheter type.

### In-depth assessment

*Review the patient's medical record:*

- insertion date
- vein used for insertion
- original catheter tip location on radiology report.

*Assess the patient.* Observe his catheter pathway for signs and symptoms of complications such as vein thrombosis and extravasation:

- engorged superficial chest wall vein
- neck or jaw pain
- hearing a gurgling sound or running stream
- swelling
- patient complaints of discomfort or pain.

*Assess the catheter:*

- patency as evidenced by blood return and flushing without resistance
- insertion site, integrity of dressing, and securement device
- external catheter length compared with external length documented at the time of insertion

- evidence of fluid leakage, noting the amount and color.

*Assess the infusion therapy:*

- drugs and fluids administered
- use of 0.9% sodium chloride solution before and after each drug and blood sampling
- compatibility of all drugs
- if compatibility unknown, investigating whether administered drugs could precipitate. If compatibility still unknown, assume incompatibility.
- pharmacy consulted for more information about drug pH.

### Appropriate responses

Use your assessment findings to determine the appropriate management.

- *Evidence of intraluminal thrombus.* Follow hospital policies and procedures to administer a fibrinolytic agent.

Use the clearance agent appropriate for the suspected drug.

- *Suspected mechanical problem.* Get an order for a chest X-ray to assess tip location and detect possible pinch-off syndrome.
- *Problem unresponsive to clearance agent or inapparent on chest X-ray.* The patient should be referred to interventional radiology for a cathetergram, venogram, or other appropriate diagnostic study.

large clot and pulmonary embolus because of its location in a large, deep vein. Signs and symptoms of phlebitis or infiltration may not appear as quickly as they would in a vein closer to the surface, so carefully assess your patient's insertion site dressing, the external catheter segment, and his entire arm.

Correct any external problem you find, such as kinking of the external catheter, but contact the I.V. team if you don't get a blood return. Remove the catheter only if you detect evidence of phlebitis or infiltration.

### Why a CVC?

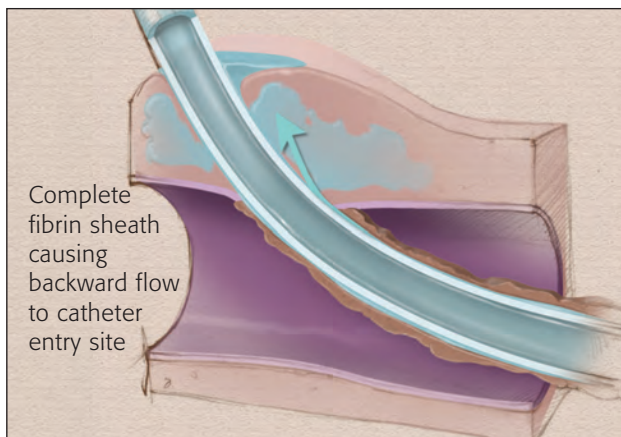
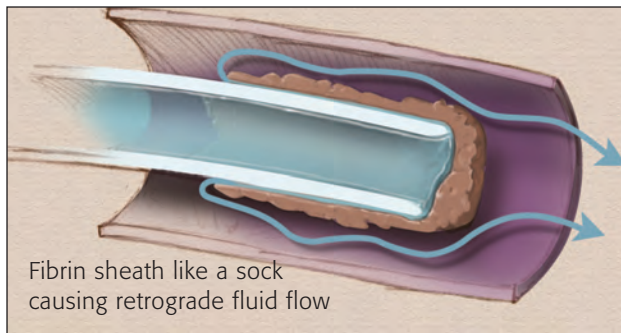
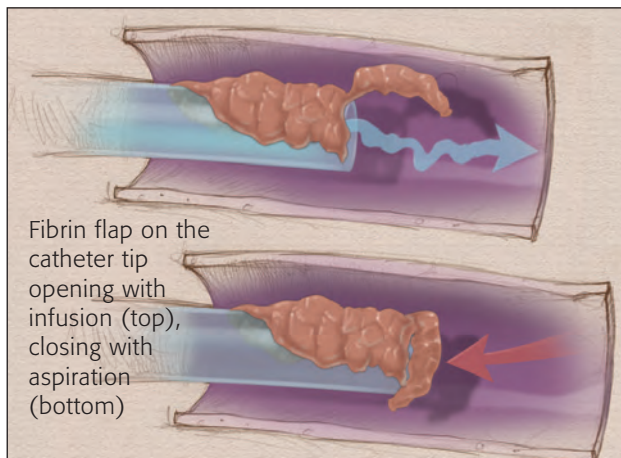
Your patient may have one of various types of CVCs inserted if peripheral venous access is limited or unavailable or if his prescribed I.V. medication is highly irritating and requires maximum hemodilution in a large central vein. A CVC is indicated to infuse continuous vesicant chemotherapy, a parenteral nutrition solution containing more than 10% dextrose or 5% protein, and any solution with a pH less than 5 or greater than 9 or osmolarity greater than 500 mOsm/liter.

The length of an individual CVC depends on its design, the patient's size, and the chosen insertion site. Many inner and outer diameters are available.

The insertion method for a PICC or a nontunneled CVC is percutaneous venipuncture; a tunneled catheter or implanted port is inserted surgically. When the CVC is inserted in an arm, subclavian, or jugular vein, its tip rests in the superior vena cava; the tip of a CVC inserted in a leg vein rests in the inferior

A **midline catheter**, typically 6 to 8 inches (15 to 20 cm) long, is positioned in the basilic or cephalic vein deep in the upper arm. Like a central venous catheter (CVC), a midline catheter poses a greater risk of a

vena cava. At the time of insertion, a chest X-ray is done to confirm proper tip location and catheter position parallel with the vein wall, and the location is documented.



- pain and swelling on the chest wall, neck, and jaw on the side of catheter insertion; in the extremity's upper portion; or in the periclavicular area (depending on insertion site)
- engorged peripheral veins on the extremity or chest wall on that side
- paresthesia or discoloration of the extremity
- loss of function in the extremity.

If you detect any of these problems, immediately investigate whether your patient's vein or the CVC is occluded.

### Problems outside the catheter

Vein thrombosis caused by a fibrin layer on the catheter, a thrombus on the vein wall or the fibrin layer, or a complete occlusive thrombus between the vein and the catheter can slow or stop the flow of blood.

A **fibrin layer** starts forming on every catheter as soon as it enters the bloodstream. Within 5 minutes, proteins binding to the catheter surface equal the protein concentration in the bloodstream. Within 24 hours, a layer of platelets and white blood cells about 1 mm thick adheres to the proteins. Depending on the patient's coagulation factors, a thrombus can build on this layer. Within a week of catheter insertion, smooth muscle cells from the injured vein wall migrate to cover the puncture site and the fibrin/thrombus layer. Within 2 weeks, more smooth muscle cells and collagen stabilize this layer.

A fibrin layer can obstruct blood flow several ways. A fibrin flap or "tail" on the catheter tip can act like a valve, opening with infusion and closing on aspiration. A fibrin sheath encasing part of the catheter and its tip, like a sock, can cause fluid leaving the tip to flow retrograde along the catheter under the sheath and enter the normal blood flow upstream at the sheath's open end. If a fibrin sheath completely covers the catheter, the fluid leaving the tip flows outside the catheter within the sheath all the way back to where the catheter enters the vein to cause extravasation injury.

A **thrombus on the vein wall** can be beneficial or it can interfere with I.V. therapy by slowing the flow of fluid or stopping it completely if the thrombus extends over the catheter lumen. Each venipuncture you perform disturbs the vein's inner layer of smooth, flat endothelial cells—the tunica intima—and triggers thrombosis. Platelets accumulate in the damaged area to initiate clotting. A stable platelet plug held together with fibrin strands traps red blood cells, forming a beneficial thrombus that stops bleeding at the puncture site. Normally, fibrinolysis destroys the thrombus when its mission is done.

### A CVC poses greater risks

A CVC stays in contact with a long vein segment, increasing the risk of complications. But removing it and inserting another would pose additional risks, such as pneumothorax and artery or nerve damage. Reinsertion can be painful, stressful, and expensive and your patient may need I.V. therapy over a long period, so make every effort to correct problems to avoid the need for catheter replacement.

Carefully assess your patient for these clinical manifestations of vein- or catheter-related thrombosis:

- inability to aspirate blood

A **veno-occlusive thrombus** extends from the vein wall to the catheter and totally occludes blood flow through the vein.

Poor venipuncture technique, traumatic catheter advancement, catheter tip impingement against the vein wall, and the infusion of irritating medications can damage the tunica intima enough to trigger dysfunctional thrombosis. The degree of trauma, the length of vein that's damaged, and the patient's blood coagulation status all play a role in the size of the thrombus.

Skillful venipuncture and slow, gentle catheter advancement minimize damage to the tunica intima to prevent harmful thrombosis. Using the smallest catheter appropriate to deliver prescribed therapy, positioning the tip so it lies parallel to the vein wall, and infusing irritating drugs into veins of maximum blood flow also reduce the risk of damage and thrombosis.

Even skillful insertion technique can't prevent thrombosis if the patient's blood is hypercoagulable. Hypercoagulable states can occur with antiphospholipid syndrome, heparin-induced thrombocytopenia, malignancy, pregnancy, hormone replacement therapy, bed rest, and deficiencies in protein S, protein C, and antithrombin.

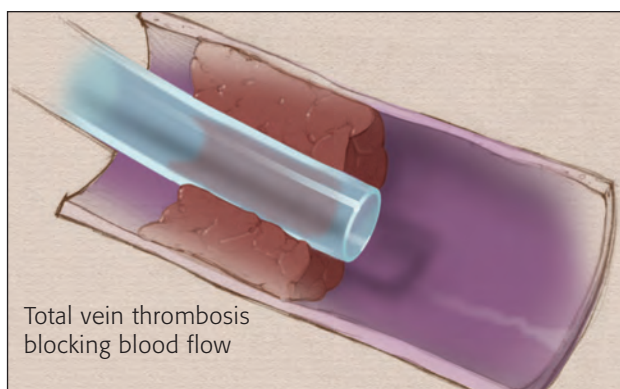
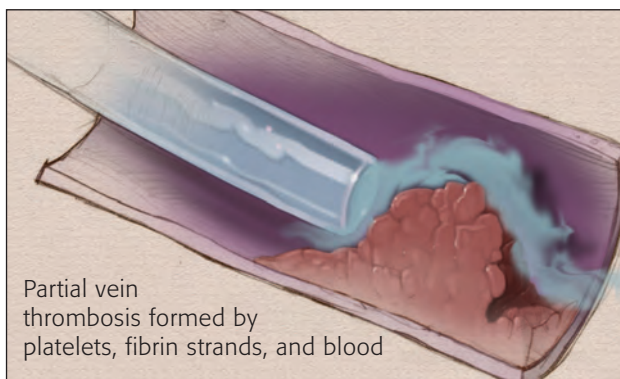
### Identifying and treating vein thrombosis

Diagnostic tests to identify vein thrombosis include color-flow duplex ultrasonography, radiographic imaging with contrast media, magnetic resonance imaging, angiography, and transesophageal echocardiography. Injecting a contrast medium through the catheter may help identify problems in the lumen or at the tip. Contrast medium injected into the vein distal to the catheter insertion site can reveal problems within the vein outside the catheter. Careful attention to the contrast pathway can reveal the presence of a fibrin sheath.

Techniques used to resolve catheter-related vein thrombosis include therapy with a fibrinolytic or anticoagulant agent.

**Catheter-directed fibrinolysis** is performed in the interventional radiology department. Small amounts of a fibrinolytic agent such as recombinant tissue plasminogen activator (t-PA, alteplase) are injected through the catheter or sprayed intermittently on the thrombus through a separate catheter inserted in the thrombus.

**Infusion of low-dose t-PA** is a promising technique of infusing small systemic doses without further invasive techniques. Although this method poses a risk of systemic fibrinolysis, the dose is only about 10% of the amount infused to combat a myocardial infarction or stroke. In studies of hemodialysis catheters, t-PA has been infused at rates from 1 to 2.5 mg/hour into



each catheter lumen for 2 to 4 hours. Hemodialysis catheters require flow rates of at least 300 ml/minute, so this method could succeed with other types of CVCs as well. The risks of a fibrinolytic infusion must be weighed against your patient's need for a CVC and the risks of removing it and inserting a new one.

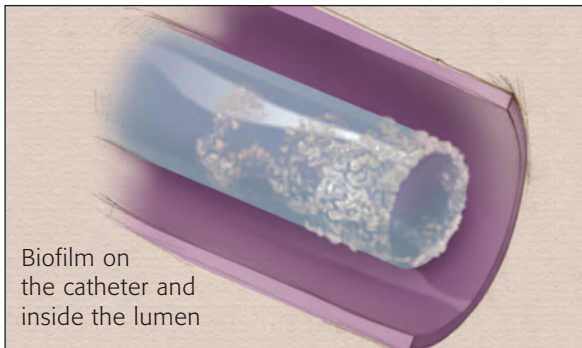The patient will also need **systemic anticoagulation**, which calls for infusing an unfractionated heparin for 5 to 10 days with overlapping warfarin therapy for 4 to 5 days. When his international normalized ratio indicates adequate anticoagulation, the heparin is discontinued and he continues warfarin therapy. If the thrombus is severe, he may have a venous stent implanted to prevent reocclusion.

### Problems within the catheter lumen

Occlusion of the catheter lumen is the most common noninfectious complication of CVCs. Affecting about one-third of all CVCs, occlusions may originate from biofilm (a slimy material containing microorganisms that coats the catheter), a thrombus, or drug precipitate. Let's look at each one.

**Biofilm on the catheter surfaces.** Like a fibrin layer, biofilm starts at the time of catheter insertion. Formed by organisms remaining on the epidermis after skin antisepsis, biofilm covers the outer surface of all vascular access devices and may occlude the CVC lumen. Regardless of how carefully you handle the catheter, organisms are introduced to its surface during venipuncture and into its lumen during infusions and manipulation of the catheter hub during tubing or cap changes, medication administration, and flushing.

A catheter that's been in place less than 10 days is



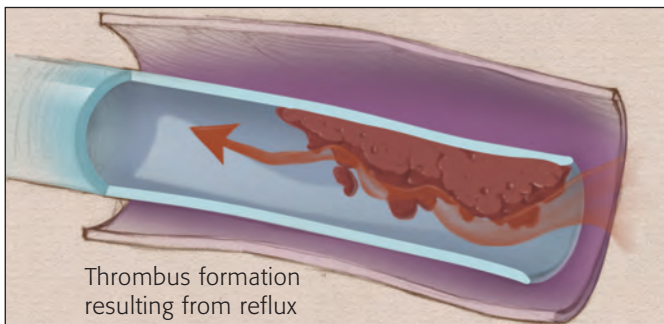
likely to have more biofilm on its outer surface. A catheter that's been dwelling for more than 30 days is likely to have more biofilm on the inner surface as more organisms are introduced into the lumen.

If fibrin or a thrombus is already occluding the catheter lumen, biofilm can compound the problem. Aggressive flushing can shear off biofilm and propel it into the bloodstream or break down the thrombus to release organisms into the bloodstream. As a result, the patient may need therapy for a bloodstream infection as well as fibrinolytic therapy.

**Thrombus in the catheter lumen.** Just as protein and fibrin from the blood collect on the catheter's outer surface, they can build up inside the catheter from blood aspirated to assess catheter patency or from blood reflux into the lumen. (See *Risking reflux* to learn about several unintentional sources.)

Treatment of an intraluminal thrombus calls for instillation of a fibrinolytic agent. The only drug indicated by the Food and Drug Administration to clear occluded catheter lumens is t-PA. Although it's packaged in unit doses, you must prepare the solution immediately before using it.

To help prevent intraluminal thrombus formation,



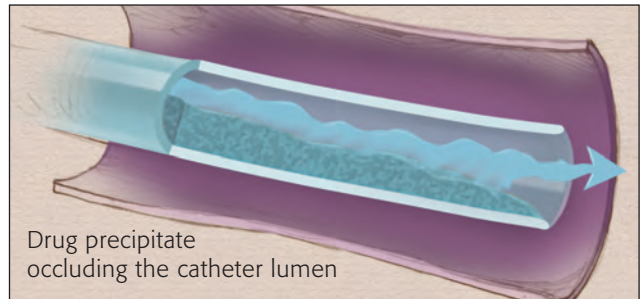
use these techniques:

- Adhere to the appropriate flushing procedure for any needleless connector system you use.
- Disconnect administration sets and flush the catheter immediately after the medication has infused.
- Teach your patient with a PICC or midline catheter to limit physical activity.

**Drug precipitates.** When incompatible drugs come in contact with each other, a physicochemical reaction

changes the solution's physical properties and a precipitate forms. The degree of incompatibility depends on such factors as how long the drugs are in contact, the mixing sequence, light exposure, and temperature.

Think of the infusion technique as a possible problem source: Will your patient's drugs be mixed in the same large-volume container (500 ml or 1,000



ml) and infused over several hours? Will they be mixed in a syringe and injected within a few minutes? Or will one drug be infused through the injection site of an administration set infusing another drug? Drug compatibility could differ in each of these situations. Refer all questions to a pharmacist who can access and interpret the latest data. Nurses with documented competency should perform the catheter clearance procedures.

Responding to drug precipitate depends on why it's formed. Acidic drugs with a very low pH can form a precipitate if the pH rises; alkaline drugs with a high pH can form a precipitate when the pH drops. Instilling hydrochloric acid to decrease the pH of acidic drugs and sodium bicarbonate to raise the pH of alkaline drugs should return the precipitate to solution.

Another type of precipitate can occur when infusion of lipid emulsions causes a waxy material to accumulate in the catheter lumen. Although the exact cause is unknown, the problem is more common when a catheter infusing parenteral nutrition is also used to infuse other medications or for blood sampling. Admixing all the components of 3-in-1 parenteral nutrition in one container might also contribute to this problem.

Instilling a small amount of ethanol, ethyl alcohol, or sodium hydroxide into the catheter should dissolve lipid precipitate. Carefully follow the manufacturer's instructions because prolonged exposure to alcohol could damage catheters made of some types of polyurethane.

### Mechanical occlusions

Many mechanical problems can occlude a CVC. External causes include a clogged in-line filter, a pinch in the external portion of the catheter, or a tight suture. Internally, the catheter could dislodge or

## RISKING REFLUX

Several factors can cause unintentional reflux into the I.V. catheter lumen:

**Syringe design.** Injecting all the fluid from a standard syringe into the catheter compresses the tip on the syringe barrel. When you release pressure on the plunger rod, the plunger rebounds and draws blood back into several centimeters of the catheter lumen. The narrower the lumen, the longer the reflux distance. Syringes specially designed for catheter flushing are available to prevent this problem.

**Needleless connection system design.** Know which type you're using.

*Negative displacement devices* let blood flow back into the catheter lumen when you disconnect the syringe or administration set. When using such a device, use one of these positive-pressure flushing techniques to prevent reflux:

- Withdraw the blunt cannula from the needleless connector as you flush the last 0.5 ml of fluid into the catheter.
- Flush all fluid into the catheter, maintain pressure on the syringe plunger, clamp the tubing between the catheter hub and the patient, then disconnect the syringe.

*Positive displacement devices* withhold a small amount of fluid to overcome blood reflux. Disconnecting the administration set or syringe forces the reserved fluid into the catheter lumen. *Don't* use positive pressure flushing techniques with this type of device, which would cause blood reflux.

*Neutral displacement devices* prevent movement of fluid or blood in either direction when you disconnect the device. This prevents blood reflux and the need to force additional fluid into the lumen.

**Aggressive flushing.** By causing turbulence in the catheter lumen, aggressive flushing can shear off biofilm and propel it into the bloodstream.

**Changes in intrathoracic pressure.** Because no valve is

located between the vena cava and the right atrium, some blood flows retrograde with every heartbeat. Coughing, sneezing, vomiting, lifting heavy objects, or heart failure can increase intrathoracic pressure, forcing blood into the catheter lumen. If the patient coughs, for example, while his catheter isn't closed or "locked," blood moves into the lumen.

**Muscle contraction.** Muscle acts as a venous pump that helps return blood to the heart. When a muscle contracts, proximal venous valves open while distal valves close. Pressure from the contracting muscle forces the locking fluid out of the catheter lumen, allowing blood reflux when the muscle relaxes.

Just as pinching a straw forces fluid from its tip, pressure from muscle contraction in an arm with a midline catheter or a PICC can compress the catheter and force fluid from it. Relieving the compression pulls blood back into the space. A patient with a PICC should perform regular activities of daily living but avoid strenuous or repetitive physical activities.

**Changes in infusion pressure.**

Venous pressure in the hand is about 35 mm Hg; at the midline tip location, it's about 8 mm Hg; in the superior vena cava, it's 0 mm Hg. Infusion pressure must be great enough to overcome venous pressure so the fluid can enter the systemic circulation. Fluid infusing by gravity from 4 feet above the patient exerts about 100 mm Hg of pressure, or 2 pounds/square inch. When the fluid container empties, infusion pressure is 0, so blood can flow backward into the catheter lumen, especially in peripheral veins. Most infusion pumps will maintain positive pressure and prevent blood reflux.

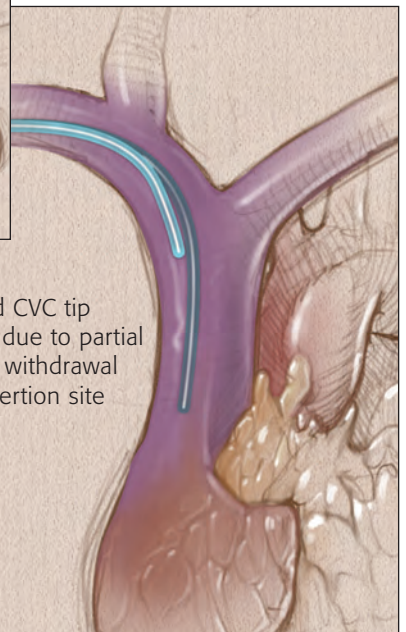
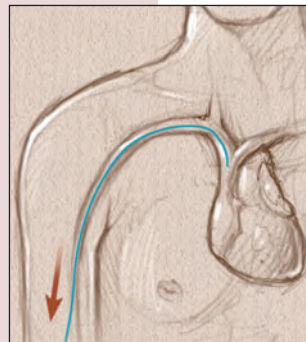
rupture, its tip could migrate, or "pinch-off syndrome" could affect a catheter positioned in a subclavian vein.

**Catheter dislodgment,** partial withdrawal from the insertion site and a change in the catheter tip location, can affect a CVC or midline catheter.

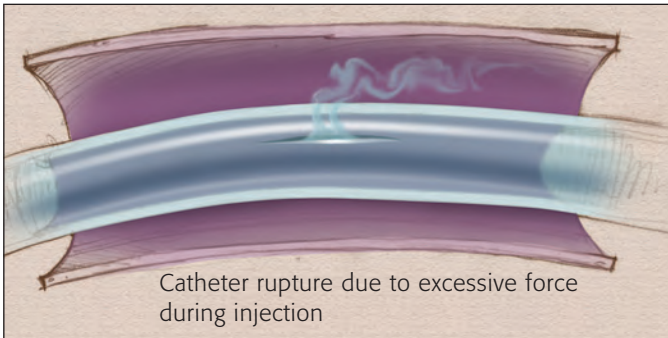
Possible causes include improper technique removing a dressing, inadequate catheter securement, and the patient's physical activity. If the catheter tip presses against the vein wall, occlusion can be immediate. Even without an occlusion, though, continued contact with the vein wall can lead to vein thrombosis.

Never try to reinsert a dislodged catheter; doing so would increase the risk of infection. Instead, measure the external catheter length and compare your measurement with the external length documented at insertion. If the measurements for a CVC differ by several centimeters, the patient needs a chest X-ray to reveal the tip location. If the X-ray shows that the tip is no longer in the vena cava, the catheter should be removed and a new one inserted. In some cases, a dislodged catheter can be removed and a new one inserted over a guidewire to avoid another insertion procedure.

If the CVC tip is still in the vena cava and functioning properly, make sure the catheter is properly secured to prevent further movement. Document your intervention.



Changed CVC tip location due to partial catheter withdrawal from insertion site



**Catheter rupture** can result from excessive force applied during an injection procedure into a midline catheter or CVC. Infusing by gravity at about 2 pounds/square inch (psi) or by infusion pump at 5 to 25 psi is safe for the catheter, but you don't know how much force you're applying to the plunger when you inject solution into the catheter from a syringe.

Always remember when you inject fluid into an I.V. catheter with a syringe that larger syringes create less pressure and smaller syringes create more. When using a syringe, take care to note resistance and never forcefully flush the catheter, regardless of the syringe size. Although large syringes are considered safer, they don't provide total protection against catheter damage. A large hand applying excessive force to the plunger of a 10-ml syringe attached to an occluded catheter produces enough intraluminal pressure to rupture the catheter or to propel a thrombus into the bloodstream.

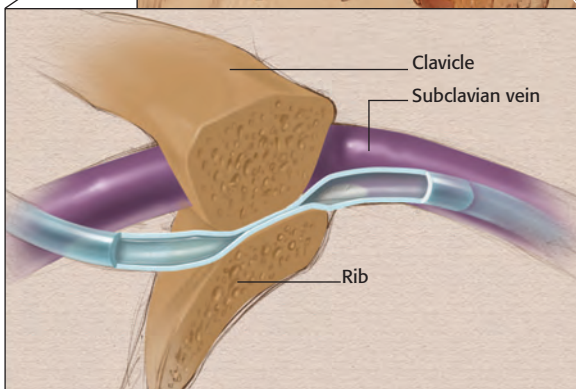
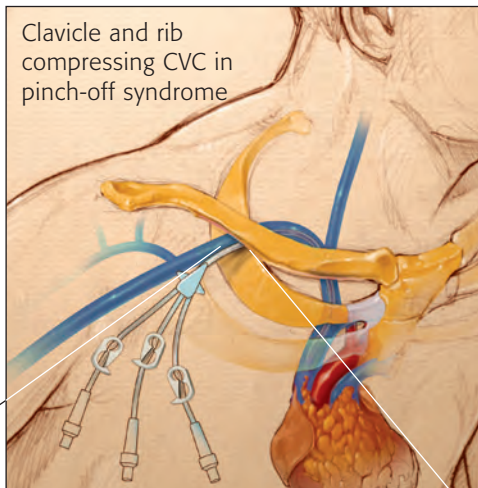
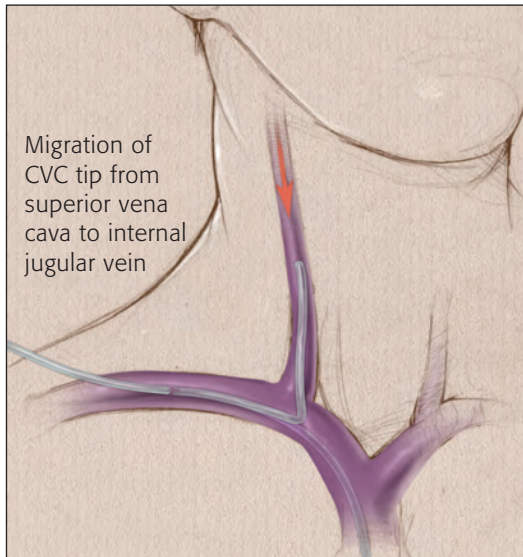
Suspect catheter rupture if infused or injected fluid leaks from the insertion site, which can occur when the damaged portion is close to the site. Assess your patient for signs of inflammation or swelling in any area of the catheter pathway or the chest wall because a leak far from the insertion site can cause infiltration or extravasation injury. Treatment options, which depend on the risks and benefits for the patient, include removing the catheter and inserting a new one or performing a catheter exchange.

**Catheter migration**, specific to CVCs, occurs when the internal catheter tip changes position without the external catheter length changing. A common example is a CVC tip moving from the superior vena cava to the internal jugular vein. The tip can migrate with changes in intrathoracic venous pressure caused by coughing, sneezing, vomiting, or heavy lifting; heart failure; or mechanical ventilation.

Catheter migration causes the infusion to flow against the direction of blood flow. This condition could cause the infusing medications to flow retrograde into the intracranial venous sinuses and trigger neurologic problems such as seizures. The catheter tip also can impinge on the vein wall to increase the risk of vein thrombosis.

Migration of a subclavian catheter to the jugular vein directs the catheter tip toward the patient's head. Infusing fluids will cause him to hear a "running stream" or gurgling sound, a phenomenon that's commonly the first clue to the problem. Stop the infusion until the tip returns to the vena cava. This might occur spontaneously or it could require a radiologic intervention.

**Pinch-off syndrome** affects only catheters inserted in the subclavian vein. During insertion, the patient is



placed in a Trendelenburg position with a rolled towel or sheet between his shoulder blades to widen the angle between the clavicle and the first rib. If the venipuncture is made medial to the midclavicular line, a small portion of the catheter outside the vein lies under the clavicle. When the patient sits up, the clavicle and rib move together and could compress the catheter in the narrow space. Over time, the compression can lead to a catheter rupture and possible embolization.

If your patient has a subclavian catheter and you can't flush it or aspirate blood, have him change the position of his arm on the catheter side by raising it or by pulling his shoulder backward. If you can then flush the catheter or get a blood return, suspect pinch-off syndrome.

Pinch-off syndrome also can affect an implanted port or a tunneled catheter, so carefully assess your patient's periclavicular area near the point where the catheter enters the vein. Check for redness, swelling, or crepitus.

A chest X-ray can show catheter compression due to pinch-off syndrome, but be sure to tell the radiology department what you suspect. Normal positioning for a chest X-ray is with the patient's shoulders rotated forward, but that position would relieve the compression. To detect pinch-off, he should be positioned with his arms freely hanging at his side.

If pinch-off syndrome is causing catheter compression, the catheter should be removed and a new one inserted from the jugular vein or lateral to the mid-

clavicular line to prevent extravasation injury and catheter embolus.

### Management and prevention

Catheter occlusion interrupts your patient's I.V. therapy, increases his risk of serious complications, and adds to the cost of care. With quick thinking and focused assessments, you can identify the problem fast and intervene effectively. Better yet, armed with your knowledge of how catheter occlusions develop, you can head off problems and keep I.V. therapy flowing smoothly. <>

#### SELECTED REFERENCES

Gorski L. Central venous access device occlusions. Part 1: Thrombotic causes and treatment. *Home Healthcare Nurse*. 21(2):115-121, February 2003.

*Infusion Nursing Standards of Practice*. Norwood, Mass., Infusion Nurses Society, 2000.

McKnight S. Nurse's guide to understanding and treating thrombotic occlusion of central venous access devices. *Medurg Nursing*. 13(6):377-382, December 2004.

Mirtallo JM. Complications associated with drug and nutrient interactions. *Journal of Infusion Nursing*. 27(1):19-24, January/February 2004.

Semba CP, et al. Treatment of central venous catheters with alteplase: Results in 1,064 patients. *Journal of Vascular and Interventional Radiology*. 13(12):1199-1205, December 2002.

Lynn C. Hadaway is president of Lynn Hadaway Associates, Inc., in Milner, Ga.

The author has disclosed that she has no significant relationship with or financial interest in any commercial companies that pertain to this educational activity.



#### SELECTED WEB SITES

Association for Vascular Access <http://www.avainfo.org>

Infusion Nurses Society <http://www.insl.org>

Lynn Hadaway Associates, Inc. <http://www.hadawayassociates.com>

Last accessed on July 6, 2005.

**C E**

**Earn CE credit online:**

**Go to <http://www.nursingcenter.com/CE/nursing> and receive a certificate *within minutes*.**

#### INSTRUCTIONS

### Reopen the pipeline for I.V. therapy

#### TEST INSTRUCTIONS

- To take the test online, go to our secure Web site at <http://www.nursingcenter.com/ce/nursing>.
- On the print form, record your answers in the test answer section of the CE enrollment form on page 62. Each question has only one correct answer. You may make copies of these forms.
- Complete the registration information and course evaluation. Mail the completed form and registration fee of \$22.95 to:  
**Lippincott Williams & Wilkins, CE Group**, 2710 Yorktowne Blvd., Brick, NJ 08723. We will mail your certificate in 4 to 6 weeks. For faster service, include a fax number and we will fax your certificate within 2 business days of receiving your enrollment form.
- You will receive your CE certificate of earned contact hours and an answer key to review your results. There is no minimum passing grade.
- Registration deadline is August 31, 2007.

#### DISCOUNTS and CUSTOMER SERVICE

- Send two or more tests in any nursing journal published by LWW together and deduct \$0.95 from the price of each test.

- We also offer CE accounts for hospitals and other health care facilities on nursingcenter.com. Call **1-800-787-8985** for details.

#### PROVIDER ACCREDITATION:

This Continuing Nursing Education (CNE) activity for 3.5 contact hours is provided by Lippincott Williams & Wilkins (LWW), which is accredited as a provider of continuing education in nursing by the American Nurses Credentialing Center's Commission on Accreditation and by the American Association of Critical-Care Nurses (AACN 00012278, CERP Category A). This activity is also provider approved by the California Board of Registered Nursing, Provider Number CEP 11749 for 3.5 contact hours. LWW is also an approved provider of CNE in Alabama, Florida, and Iowa, and holds the following provider numbers: AL #ABNP0114, FL #FBN2454, IA #75. All of its home study activities are classified for Texas nursing continuing education requirements as Type 1. *Your certificate is valid in all states. This means that your certificate of earned contact hours is valid no matter where you live.*



## Reopen the pipeline for I.V. therapy

**GENERAL PURPOSE** To teach nurses problem-solving techniques for I.V. therapy via peripheral catheters and CVCs.

**LEARNING OBJECTIVES** After reading the preceding article and taking this test, you should be able to: **1.** Identify the problems associated with each type of I.V. catheter. **2.** Indicate interventions to help prevent I.V. catheter complications. **3.** Identify management strategies for complications associated with peripheral catheters and CVCs.

**1. If the patient's skin at the insertion site of a short peripheral I.V. catheter is cool, swollen, and numb, you should**

- a. flush the catheter with saline and heparin.
- b. continue the infusion and ask the primary care provider to evaluate the site.
- c. immediately remove the catheter.
- d. slow the I.V. rate, then reassess the site in an hour.

**2. If aspiration from a short peripheral I.V. catheter doesn't produce a blood return, you should**

- a. immediately replace the catheter.
- b. increase the drip rate to determine if the catheter is patent.
- c. try other ways to get a blood return.
- d. flush the catheter with saline and aspirate again.

**3. Which of the following correctly describes a midline catheter?**

- a. Placement is in the basilic or cephalic vein in the upper arm.
- b. The length is less than 3 inches.
- c. Insertion is performed surgically.
- d. The tip rests in the superior vena cava.

**4. What risk of large clots and pulmonary emboli does a midline catheter in a large,**

**deep vein pose when compared with a peripheral catheter in a small vein?**

- a. the same risk
- b. less risk
- c. a greater risk
- d. no risk

**5. Which of the following is an indication to use a CVC?**

- a. I.V. therapy for all elderly patients, who tend to have frail skin
- b. highly irritating I.V. medication
- c. medications that must be administered by I.V. push
- d. I.V. therapy for young children who tend to pull out peripheral lines

**6. The tip of a CVC inserted in a leg vein should rest in the**

- a. femoral vein.
- b. iliac vein.
- c. inferior vena cava.
- d. renal vein.

**7. Which technique is used to determine proper CVC placement?**

- a. aspirating for blood return with a large syringe
- b. holding the I.V. bag lower than the catheter and watching for blood return
- c. injecting a contrast medium through the catheter, then performing a CT scan
- d. performing a chest X-ray to confirm catheter tip location

**8. Pain and swelling in the patient's chest wall, neck, and jaw on the side of CVC insertion are signs and symptoms of**

- a. pinch-off syndrome.
- b. vein or catheter thrombosis.
- c. infusing irritating medications.
- d. pneumothorax.

**9. Which of the following correctly describes a fibrin layer on an I.V. catheter?**

- a. It starts forming on every catheter as soon as it enters the bloodstream.
- b. It's a buildup of plaque 1 cm thick.
- c. It causes high levels of T lymphocytes to bind to the catheter surface.
- d. It develops into a layer of red blood cells and proteins within 24 hours.

**10. Which statement correctly describes a fibrin layer?**

- a. It can form a flap on the catheter tip and act like a valve.
- b. It develops when the tunica intima is damaged.
- c. It's a thrombus extending from the vein wall to the catheter.
- d. It occurs when platelets accumulate in a damaged area.



**ENROLLMENT FORM** *Nursing2005, August, Reopen the pipeline for I.V. therapy*

**A. Registration Information:**

Last name \_\_\_\_\_ First name \_\_\_\_\_ MI \_\_\_\_\_  
 Address \_\_\_\_\_  
 City \_\_\_\_\_ State \_\_\_\_\_ ZIP \_\_\_\_\_  
 Telephone \_\_\_\_\_ Fax \_\_\_\_\_ E-mail \_\_\_\_\_

LPN  RN  CNS  NP  CRNA  CNM  other \_\_\_\_\_  
 Job title \_\_\_\_\_ Specialty \_\_\_\_\_  
 Type of facility \_\_\_\_\_ Are you certified?  Yes  No  
 Certified by \_\_\_\_\_  
 State of license (1) \_\_\_\_\_ License # \_\_\_\_\_  
 State of license (2) \_\_\_\_\_ License # \_\_\_\_\_  
 Social Security # \_\_\_\_\_

**Registration Deadline:** August 31, 2007

Contact hours: 3.5 Pharmacology hours: 0.0 Fee: \$22.95

From time to time, we make our mailing list available to outside organizations to announce special offers. Please check here if you do not wish us to release your name and address.

**B. Test Answers: Darken one circle for your answer to each question.**

a	b	c	d	a	b	c	d	a	b	c	d	a	b	c	d	a	b	c	d
1. <input type="radio"/>	<input type="radio"/>	<input type="radio"/>	<input type="radio"/>	8. <input type="radio"/>	<input type="radio"/>	<input type="radio"/>	<input type="radio"/>	15. <input type="radio"/>	<input type="radio"/>	<input type="radio"/>	<input type="radio"/>	22. <input type="radio"/>	<input type="radio"/>	<input type="radio"/>	<input type="radio"/>	29. <input type="radio"/>	<input type="radio"/>	<input type="radio"/>	<input type="radio"/>
2. <input type="radio"/>	<input type="radio"/>	<input type="radio"/>	<input type="radio"/>	9. <input type="radio"/>	<input type="radio"/>	<input type="radio"/>	<input type="radio"/>	16. <input type="radio"/>	<input type="radio"/>	<input type="radio"/>	<input type="radio"/>	23. <input type="radio"/>	<input type="radio"/>	<input type="radio"/>	<input type="radio"/>	30. <input type="radio"/>	<input type="radio"/>	<input type="radio"/>	<input type="radio"/>
3. <input type="radio"/>	<input type="radio"/>	<input type="radio"/>	<input type="radio"/>	10. <input type="radio"/>	<input type="radio"/>	<input type="radio"/>	<input type="radio"/>	17. <input type="radio"/>	<input type="radio"/>	<input type="radio"/>	<input type="radio"/>	24. <input type="radio"/>	<input type="radio"/>	<input type="radio"/>	<input type="radio"/>	31. <input type="radio"/>	<input type="radio"/>	<input type="radio"/>	<input type="radio"/>
4. <input type="radio"/>	<input type="radio"/>	<input type="radio"/>	<input type="radio"/>	11. <input type="radio"/>	<input type="radio"/>	<input type="radio"/>	<input type="radio"/>	18. <input type="radio"/>	<input type="radio"/>	<input type="radio"/>	<input type="radio"/>	25. <input type="radio"/>	<input type="radio"/>	<input type="radio"/>	<input type="radio"/>	32. <input type="radio"/>	<input type="radio"/>	<input type="radio"/>	<input type="radio"/>
5. <input type="radio"/>	<input type="radio"/>	<input type="radio"/>	<input type="radio"/>	12. <input type="radio"/>	<input type="radio"/>	<input type="radio"/>	<input type="radio"/>	19. <input type="radio"/>	<input type="radio"/>	<input type="radio"/>	<input type="radio"/>	26. <input type="radio"/>	<input type="radio"/>	<input type="radio"/>	<input type="radio"/>				
6. <input type="radio"/>	<input type="radio"/>	<input type="radio"/>	<input type="radio"/>	13. <input type="radio"/>	<input type="radio"/>	<input type="radio"/>	<input type="radio"/>	20. <input type="radio"/>	<input type="radio"/>	<input type="radio"/>	<input type="radio"/>	27. <input type="radio"/>	<input type="radio"/>	<input type="radio"/>	<input type="radio"/>				
7. <input type="radio"/>	<input type="radio"/>	<input type="radio"/>	<input type="radio"/>	14. <input type="radio"/>	<input type="radio"/>	<input type="radio"/>	<input type="radio"/>	21. <input type="radio"/>	<input type="radio"/>	<input type="radio"/>	<input type="radio"/>	28. <input type="radio"/>	<input type="radio"/>	<input type="radio"/>	<input type="radio"/>				

**C. Course Evaluation\***

1. Did this CE activity's learning objectives relate to its general purpose?  Yes  No  
 2. Was the journal home study format an effective way to present the material?  Yes  No  
 3. Was the content relevant to your nursing practice?  Yes  No  
 4. How long did it take you to complete this CE activity? \_\_\_\_\_ hours \_\_\_\_\_ minutes  
 5. Suggestion for future topics \_\_\_\_\_

**D. Two Easy Ways to Pay:**

Check or money order enclosed (Payable to Lippincott Williams & Wilkins)  
 Charge my  Mastercard  Visa  American Express  
 Card # \_\_\_\_\_ Exp. date \_\_\_\_\_  
 Signature \_\_\_\_\_

\*In accordance with the Iowa Board of Nursing administrative rules governing grievances, a copy of your evaluation of the CE offering may be submitted directly to the Iowa Board of Nursing.

**11. What's injected into the catheter during catheter-directed fibrinolysis to relieve obstruction?**

- a. alteplase
- b. contrast medium
- c. low-molecular-weight heparin
- d. unfractionated heparin

**12. When an I.V. catheter is inserted, which of the following immediately develops on its surface?**

- a. infiltrate
- b. biofilm
- c. precipitate
- d. thrombus

**13. Which statement correctly describes biofilm on a CVC catheter that's been in place longer than 30 days?**

- a. None is present.
- b. The inner and outer catheter surfaces will have equal amounts.
- c. The outer surface will probably have more.
- d. The inner surface will probably have more.

**14. What can happen if aggressive flushing shears off biofilm?**

- a. The catheter can migrate, making removal necessary.
- b. The biofilm can be propelled into the bloodstream and cause an infection.
- c. The biofilm can adhere to the catheter surface and cause dislodgment.
- d. The biofilm can cause infection at the catheter insertion site.

**15. The only drug approved by the FDA to clear a thrombus from a CVC is**

- a. urokinase.
- b. reteplase.
- c. t-PA.
- d. streptokinase.

**16. Which of the following correctly describes t-PA?**

- a. It prevents further thrombus formation.
- b. You must prepare the solution immediately before use.
- c. It isn't indicated by the FDA to clear an occluded CVC lumen.
- d. It's packaged in multidose vials.

**17. To help prevent a PICC intraluminal thrombus, do all the following except**

- a. telling the patient to remain supine during infusions.
- b. following appropriate flushing guidelines for the needleless system being used.
- c. flushing the catheter immediately after the medication has infused.
- d. advising the patient to limit activity.

**18. What forms when an I.V. solution changes as a result of incompatible drugs coming in contact with each other?**

- a. biofilm
- b. fibrin layer
- c. thrombus
- d. precipitate

**19. Instilling which of the following can return acidic drug precipitate to a solution?**

- a. hydrochloric acid
- b. 0.9% sodium chloride
- c. sodium bicarbonate
- d. sodium hydroxide

**20. How can you remove a lipid accumulation from an I.V. catheter?**

- a. Inject a small dose of t-PA into it.
- b. Instill a small amount of ethanol or ethyl alcohol.
- c. Flush the catheter with heparin.
- d. Aspirate until you see blood return.

**21. Improper technique removing a CVC dressing can cause**

- a. a change in the catheter tip location.
- b. formation of a fibrin layer.
- c. a pulmonary embolism.
- d. a veno-occlusive thrombus.

**22. What's the most appropriate initial intervention when you suspect a PICC is dislodged?**

- a. Remove it immediately.
- b. Verify displacement by measuring the external catheter length and comparing it with the documented insertion length.
- c. Make sure the patient has an ultrasound to verify tip placement.
- d. Advance the catheter to its former position.

**23. Which complication is most likely if excessive force is applied during injection into a CVC or midline catheter?**

- a. catheter dislodgment
- b. fibrin sheath formation
- c. catheter rupture
- d. migration of the catheter

**24. When injecting fluid from a syringe into an I.V. catheter, you should**

- a. apply as much force as needed to overcome any resistance.
- b. keep injecting even if fluid leaks from the insertion site.
- c. remember that larger syringes create less pressure than smaller ones.
- d. remember that large syringes totally protect against catheter damage.

**25. A patient with a subclavian catheter who hears a "running stream" sound is experiencing the first sign of**

- a. catheter occlusion.
- b. catheter migration.

- c. infection at the CVC site.
- d. pinch-off syndrome.

**26. A CVC inserted into the subclavian vein may become compressed between the clavicle and the first rib. This can lead to**

- a. catheter rupture.
- b. phlebitis.
- c. inflammation.
- d. thrombosis.

**27. The inability to flush or aspirate blood from a subclavian CVC unless the patient lies in a very specific position is a typical presentation of**

- a. catheter dislodgment.
- b. catheter migration.
- c. drug precipitate.
- d. pinch-off syndrome.

**28. What's the proper position for a patient having a chest X-ray to detect pinch-off syndrome?**

- a. arms freely hanging at his side
- b. arms over his head
- c. shoulders rotated forward
- d. shoulders rotated backward

**29. Which of the following can you safely administer through a short peripheral I.V. catheter?**

- a. continuous vesicant chemotherapy
- b. solutions with osmolarity greater than 500 mOsm/liter
- c. parenteral nutrition containing more than 10% dextrose
- d. solutions with a pH between 5 and 9

**30. What should you do if you suspect a mechanical problem with a CVC?**

- a. Request an order for a chest X-ray to assess tip location.
- b. Request an order for t-PA to correct the problem.
- c. Prepare for removal of the catheter.
- d. Aggressively flush the catheter with heparinized saline.

**31. Hypercoagulable states can occur with**

- a. protein A deficiency.
- b. antithrombin excess.
- c. heparin-induced thrombocytopenia.
- d. protein D deficiency.

**32. Unintentional blood reflux into the I.V. catheter lumen can occur with any of the following except**

- a. vomiting.
- b. an empty I.V. fluid bag.
- c. injecting all the fluid from a standard syringe.
- d. using a neutral displacement device.

Copyright of Nursing is the property of Springhouse Corporation. The copyright in an individual article may be maintained by the author in certain cases. Content may not be copied or emailed to multiple sites or posted to a listserv without the copyright holder's express written permission. However, users may print, download, or email articles for individual use.